



PAWERFUL STORIES

In our PAWerful Stories series, we feature furry patients and highlight WIMBA's role in restoring their mobility.

Meet Frankie, an eight-year-old German Shepherd who despite the severity of his condition remains active.



Frankie

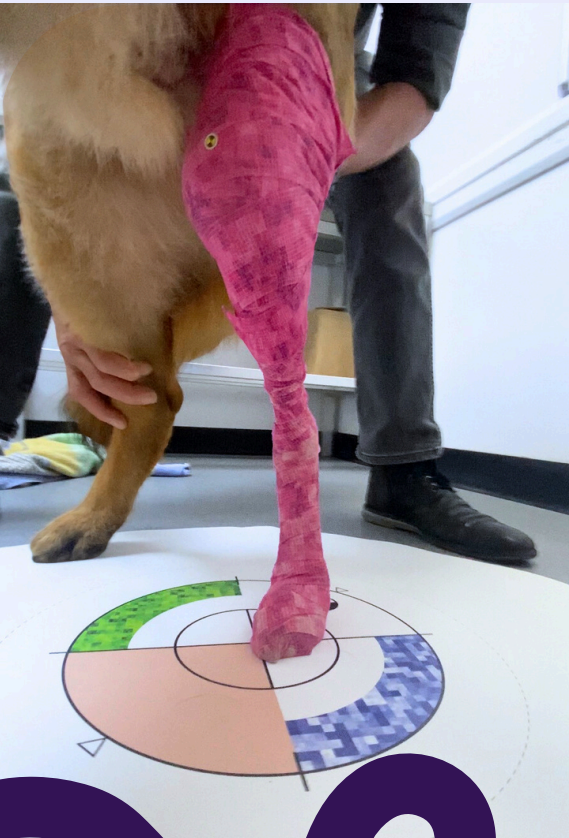- **Weight:** 39.8 kg
- **Age:** 8 years
- **Breed:** German Shepherd
- **Diagnosis:** ACL rupture/CrCCL; end-stage stifle disease with advanced osteoarthritis and stifle joint instability
- **WimbaTHERAPY:** Normal Range of Motion 120° (FLX 35°- EXT 155°)
- **WIMBA Provider:** Bridge Veterinary Centre



MEDICAL EXAMINATION

Frankie's case is characterized by a complex and chronic progression of stifle joint pathology. Initially diagnosed with Osteochondritis Dissecans (OCD) of the stifle, Frankie underwent surgical intervention. However, subsequent complications included a medial patella luxation, which was treated with a nylon suture by a referral veterinarian. Over the years, Frankie experienced recurrent joint infections, particularly following the removal of the nylon suture, which led to further joint complications.

The chronic nature of these infections resulted in the erosion of the menisci and the degeneration of both cruciate ligaments. Additionally, Frankie suffers from atopic skin disease, further complicating his case. Despite the severity of his condition, including advanced osteoarthritis and instability of the stifle joint, Frankie remains surprisingly active with a full range of motion. The prognosis was poor, with the final option being amputation if conservative management failed.



Bridge Veterinary Centre is a prominent veterinary practice in the Welsh valleys, staffed by a dedicated team of eight veterinarians, along with veterinary nurses and support staff. The center is committed to providing high-quality, compassionate care, offering a range of services from routine vaccinations and neutering to complex medical and surgical procedures.

VETERINARIAN'S GOALS

Given the complexity of Frankie's condition, the primary objective was to provide structural support to the stifle joint. The goal was to enhance Frankie's quality of life by facilitating safer, pain-reduced movement while minimizing the risk of further injury. The expectations were realistic, focusing on maintaining mobility and comfort rather than complete restoration of function.

PET OWNER'S ASPIRATIONS

Frankie's owner was seeking a solution that would allow more confident and worry-free daily walks, a key aspect of their relationship and Frankie's well-being. The owner's aspirations were aligned with the veterinarian's goals—aiming to improve Frankie's mobility while ensuring his comfort and safety during physical activity. The primary focus was on quality of life improvements rather than curative measures.

THE WIMBA ORTHOSIS IMPACT

The introduction of the WIMBA stifle orthosis resulted in immediate and noticeable improvements in Frankie's mobility. The custom-fit orthosis was well-aligned with Frankie's joints, and the owner and veterinarian reported significant improvement in Frankie's ability to rise from a resting position, a critical marker of success.

The brace is now an integral part of Frankie's physiotherapy regimen, used precisely as intended: to support and stabilize the stifle joint during exercise. Dr. Graham Blow, BVSc MRCVS, who managed Frankie's case, reported ease in both the application and removal of the orthosis, noting that the device was straightforward to use, with no difficulties in securing the components or adjusting the WIMBA tokens.

While the initial fitting required some adjustments, such as replacing the longer straps with shorter Velcro ones and updating fasteners, these were promptly addressed by WIMBA. Despite these minor modifications, the overall experience was rated highly by all parties involved.

THE REHABILITATION OF FRANKIE

"Frankie was referred for physiotherapy following multiple stifle surgeries. The referral surgeon commented that his stifle was an end stage diseased joint, his synovium had been resected because it was necrotic and the cranial and caudal cruciate ligaments were no longer present. Frankie has a very unstable stifle, cranial tibial thrust visible under load at walk, alongside internal rotation of the tibia and hyperextension of the stifle. He has been through so much in his life and our main objectives for Frankie were for him to live his best life every day, be able to go and walk in the fields and walk with his best friend Freddi.


Once his WIMBA stifle brace was fitted, it allowed him the freedom of being off lead with his friend. Frankie is now living his best life with the help of his Wimba stifle brace."




Nichi Cockburn RVN NCert (A&CC) CCRP AdvCertVPhys MIRVAP (VP)
Veterinary Physiotherapist & Rehabilitation Service Lead
VetPartners Practices Limited T/A Valley Vets

valleyvets

Nichi Cockburn RVN NCert (A&CC) CCRP AdvCertVPhys MIRVAP (VP) has been a Registered Veterinary Nurse for over 20 years, many of these years were in emergency and critical care. She refocused her training in rehabilitation and physiotherapy and gained her Certified Canine Rehabilitation Practitioner (CCRP) qualification, awarded by the University of Tennessee in 2015 and an Advanced Certificate in Veterinary Physiotherapy in 2017. Nichi leads the rehabilitation service at Valley Veterinary Hospital in Cardiff. She works closely with their multidisciplinary team, to develop an individual care package for pain management and rehabilitation. She has a particular passion in the management of osteoarthritis and is on the board of directors of the Veterinary Osteoarthritis Alliance (VOA).





"Having known Frankie and his owner since a puppy and the multiple surgical procedures he went through, he has been an incredibly brave and tolerant patient. He had recurrent resistant infections of the stifle and skin, requiring corticosteroids at times making his treatment and recovery even more difficult.

When a brace was mentioned to offer him stability and the owner to feel more confident in exercising him, WIMBA appeared to be and ultimately proved a good choice.

As it was one of the first to be made for the stifle there were a number of teething problems, but WIMBA were able to respond and make innovative and effective changes to the structure to improve its efficacy.

Frankie, his brace, the perseverance of the owner and Nichi the physio have made a great difference to his quality of life and it is great to see him thrive."

Graham Blow BVSc MRCVS
Bridge Veterinary Centre



Graham qualified in South Africa in 1985 and, after spending two years as a military vet working primarily with horses and, to a lesser extent, dogs, he then spent a year at the PDSA in Cape Town, gaining extensive and varied surgical experience across species.

Graham has been with Bridge Vets since 1989 and became a partner. He values building strong relationships with clients and takes seriously the trust they place in him, striving to ensure a pain-free and fulfilling bond between owner and patient. He enjoys general practice, with a particular interest in all forms of surgery, especially orthopaedics and complex tumour removal.

Outside of work, he enjoys walking his two dogs, beekeeping, blacksmithing, woodworking, golf, paddleboarding, and spending quality time with his family, especially his grandchildren.

